

# Fast Field-Cycling MRI identifies ischaemic stroke at ultra-low magnetic field strength.

<sup>1</sup> M.J. Macleod, <sup>2</sup> L.M. Broche, <sup>2</sup> P.J. Ross, <sup>1</sup> G. Guzman-Gutierrez,  
<sup>2</sup> A.D. Murray, <sup>2</sup> D.J. Lurie

<sup>1</sup>Acute Stroke Unit, Aberdeen Royal Infirmary <sup>2</sup>Aberdeen Biomedical Imaging Centre, School of Medicine, Medical Sciences & Nutrition, University of Aberdeen, Aberdeen AB25 2ZD

**Introduction:** Fast Field-Cycling MRI<sup>1</sup> (FFC-MRI) is a novel MRI technique in which the external magnetic field is switched during the imaging experiment. By doing this, FFC-MRI gains access to information which is invisible to conventional MRI scanners, including the variation of T<sub>1</sub> with magnetic field which is known as T<sub>1</sub> dispersion. In this work we aimed to assess whether we can identify recent cerebral infarcts at ultra-low field strength, when compared with conventional imaging.

**Methods:** After informed consent, a group of patients (n=9) with ischemic stroke were scanned within 24-96h of presentation. The FFC-MRI examination took 45 minutes, and included FFC images at five evolution fields (0.2mT to 0.2T). Patients also had CT and/or 3T MRI images available. In 4 patients the FFC-MRI single slice missed a small cortical or lacunar infarct, thus images were available for five patients.

**Results:** In patients with sub-acute ischaemic stroke, T<sub>1</sub>-weighted FFC-MRI images exhibited hyper-intense regions, with contrast increasing markedly as the evolution magnetic strength field decreased, to a maximum at the lowest field used (0.2 mT). The infarct region measured by FFC-MRI correlated well with the abnormality in CT and/or DWI images (Examples in Fig 1,2).

**Discussion:** This is the first-ever clinical application of this new modality, proving that FFC-MRI can generate diagnostic-quality images of ischaemic stroke at ultra-low magnetic fields (e.g. 0.2 mT), with significantly enhanced endogenous T<sub>1</sub>-contrast compared to conventional MRI. These exciting findings have implications for future development of a new and safe imaging modality not only for stroke but many other clinical conditions.

**Acknowledgements:** This project has received funding from the European Union's Horizon 2020 research and innovation programme under grant agreement No 668119 (project "IDentIFY").

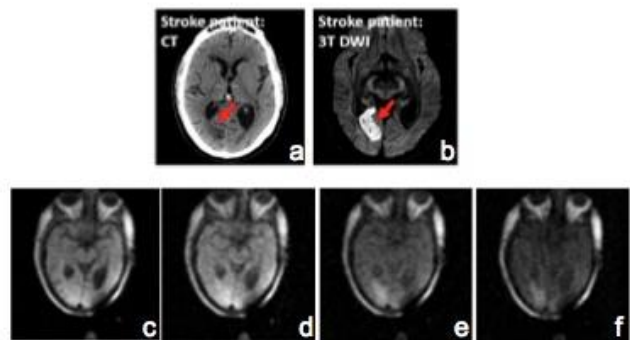


Figure 1. CT, 3T DWI MRI and FFC MRI images from a 67 year old male admitted with a right occipital infarct. a) CT at 24 hours after onset, b) 3T DWI image at 78 hours after onset c-f) FFC-MRI inversion-recovery images at the level of the lesion at 200mT, 50mT, 2mT and 0.2mT respectively (75 hours after onset).

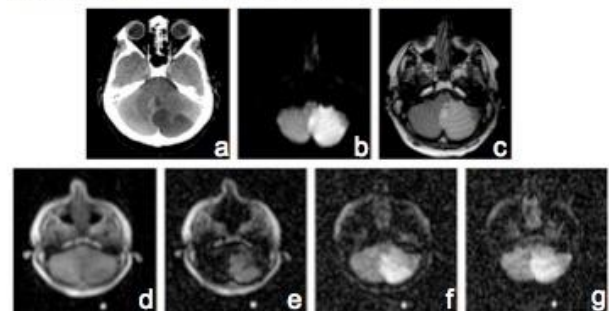


Figure 2. CT, 3T MRI and FFC MRI images from a 50 year old male admitted with a posterior inferior cerebral artery territory infarct. a) CT at 24 hours after onset, b) 3T DWI image at 96 hours after onset c) 3T T2 weighted image at 96 hours after onset d-g) FFC-MRI inversion-recovery images at the level of the lesion at 200mT, 2.2mT, 2mT and 0.2mT respectively (90 hours after onset).

1. Lurie, D. J. *et al.* Fast field-cycling magnetic resonance imaging. *Comptes Rendus Phys.* **11**, 136–148 (2010).